

Patient Information		<b>GEISINGER</b> MEDICAL LABORATORIES
Name: <b>TESTING, ADAM L</b> DOB (AGE) Sex: 3/3/1985 (24) M MRN (Client MRN): XSACH-5232268		
Billing #: 3072519 Order #:		
Client Information	Specimen Information	
Location: A7 Copy To: Outside Client.:	Collected Date: 6/17/2009 Accession Date: 6/17/2009 Reported Date: 6/17/2009 Submitting: 107 - KEITH GIBSON, MD	Accession #: <b>B09-8</b> Client Case #: Report Type: Final Report

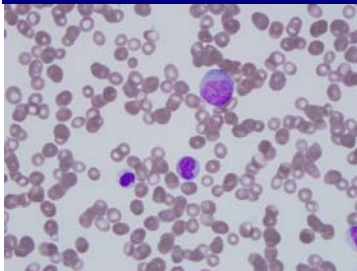
**BONE MARROW INTERPRETATION**  
 Electronically Signed Out: Kai Zhang, M.D. - GMC Lab

Bone marrow aspirate, trephine biopsy, and clot section: Acute myeloid leukemia with myelodysplasia-related changes.

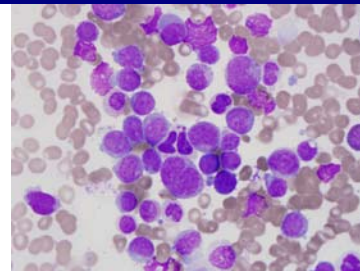
**Clinical History**

History of myelodysplastic syndrome

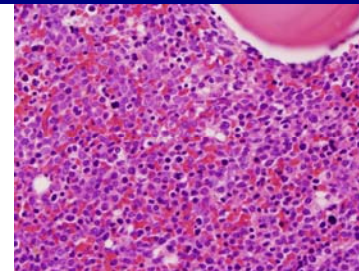
**Microscopic Findings**



blood film



BM aspirate



BM core biopsy

	Peripheral Blood (%)	Bone Marrow (%)	Reference Range (%)
<b>Myeloblasts</b>	27	55	<b>0-5</b>
<b>Promyelocytes</b>		0	<b>1-8</b>
<b>Myelocytes</b>		5	<b>5-20</b>
<b>Metamyelocytes</b>	6	5	<b>13-32</b>
<b>Band neutrophils</b>	13	5	<b>6-30</b>
<b>Segmented neutrophils</b>	0	0	<b>7-30</b>
<b>Segmented eosinophils</b>	2	15	<b>0-4</b>
<b>Segmented basophils</b>	4	0	<b>0-1</b>
<b>Nucleated RBCs</b>		10	<b>15-36</b>
<b>Lymphoblasts</b>		10	<b>0-1</b>
<b>Lymphocytes</b>	33	2	<b>3-24</b>
<b>Monoblasts</b>		1	<b>0-1</b>
<b>Monocytes</b>	15	1	<b>0-3</b>
<b>Plasma cells</b>		1	<b>0-2</b>

CBC	
<b>WBC</b>	8.3 10 <sup>3</sup> /μL
<b>RBC</b>	3.1 10 <sup>12</sup> /L
<b>HGB</b>	9.9 g/dL
<b>HCT</b>	28.4 %
<b>MCV</b>	90.5 fl
<b>MCH</b>	31.5 pg
<b>MCHC</b>	34.8 g/dL
<b>RDW</b>	17.6 %
<b>PLT</b>	30.1 10 <sup>3</sup> /μL
<b>RETIC</b>	1.0 %

**PERIPHERAL BLOOD:** Normochromic and normocytic anemia is observed. Some anisocytosis is present. Leukemic blasts are noted, comprising approximately 27% of leukocytes. The blasts are medium to large sized cells with finely dispersed nuclear chromatin with one prominent nucleolus, scant amount of cytoplasm containing rare granules. Auer

*Photographic images and diagrams represent key findings in this case; they are not intended to replace a complete review of the final diagnostic report.*

*The following statement applies to Flow Cytometry, Immunohistochemistry, Molecular Genetics, Immunofluorescence, and In situ Hybridization Assays: This test was developed and its performance characteristics determined by Geisinger Medical Laboratories. It has not been cleared or approved by the U.S. Food and Drug Administration. The FDA has determined that such clearance or approval is not necessary. This test is used for clinical purposes. It should not be regarded as investigational or for research.*

Rods are not observed. No monocytosis is present. Lymphocytes are normal. Platelets are decreased with occasional large ones; no platelet clumps are seen.

**BONE MARROW ASPIRATE:** The aspiration slides are hypercellular. Megakaryocytes are decreased with normal morphology. Numerous leukemic blasts are present, comprising approximately 55% of nucleated marrow cells. The morphologic features of the blasts are similar to the features of leukemic blasts of the peripheral blood. Dysgranulopoiesis is observed with left shift. Some dyspoietic granulocytes show hypo-granulation and hyposegmentation. Also present is evidence of mild dyserythropoiesis. Monocytes and lymphocytes are normal. No basophilia or eosinophilia is seen.

**IRON STATUS:** Iron store is increased. Many ringed sideroblasts are present, comprising approximately 45% of nucleated red blood cells.

**BONE MARROW BIOPSY and CLOT SECTION:** The core biopsy sample measures 2.8 cm. in length. It is markedly hypercellular (approximately 100%) for the patient's age. Sheets of leukemic blasts replace the marrow space. Megakaryocytes are decreased. There are a few scattered dyspoietic granulocytes and erythroid precursors. No evidence of lymphoid or epithelial infiltrates is seen. Clot section reveals similar morphologic alterations.

CPT Code(s): A: 88305,85060,85097,88313,88311